



Int J Pharm Gen Res

International Journal of
ADVANCED
PHARMACEUTICAL
GENUINE RESEARCH

www.ijapgr.com/archives/

Research article

Wound-healing potential of aqueous and ethanolic extracts of *thespesia macrophylla* blume. roots - A preliminary study

Swetha. P*², RajKumar. M¹, Krishnamoorthy.B², Muthukumaran.M²,Sujana.V²

¹Department of Pharmacognosy, Padmavathi College of Pharmacy & Research Institute, TamilNadu

²Montessori Siva Sivani Institution of Science & Technology-College of Pharmacy, Andhra Pradesh
(Received: 18 September 2013; Accepted: 30 September 2013)

Abstract



Thespesia macrophylla blume is a medicinal plant which is used from time immemorial for treatment of various disorders especially cuts, burns and wounds. The objective of this study was to verify the traditional claims by aqueous and ethanolic extracts of the root part of *Thespesia macrophylla* for its wound healing property by using animal models. Excision and Incision wound models were adopted and animals were divided into four groups of control and treatments. The animal groups were topically treated with prepared ointment containing 5%w/w of aqueous and ethanol extracts of *Thespesia macrophylla* and nitrofurazone ointment respectively. The progressive changes in wound area were monitored planimetrically by tracing the wound margin on graph paper every alternate day. It was observed that the wound contracting ability of the 5% (w/w) ethanolic extract ointment treated groups showed significant wound healing from the sixth day onwards. The tissue regeneration was much greater in the wound skin treated with 5%w/w ethanolic extract ointment than 5% w/w aqueous ointment treated without any edema, congestion, or inflammatory changes. In conclusion, the alcoholic extract of *Thespesia macrophylla* significantly enhanced and accelerated the rate of wound healing enclosure in rats.

Corresponding author

Tel +918978933078

¹Department of Pharmacognosy
Padmavathi College of Pharmacy &
Research Institute.
Dharmapuri, TamilNadu, India
reach.swethaa@gmail.com

Key Words

Thespesia macrophylla Blume,
Wound healing,
Ethanolic root extract,
wistar albino rats.

INTRODUCTION

A wound is a disruption in the continuity of cells—anything that causes cells that would normally be connected to become separated. It is an intricate process in which the skin repairs itself after injury. In normal skin, the epidermis and dermis exists in steady-state equilibrium, forming a protective barrier against the external environment. Wound healing is the process of repair that follows injury to the skin and other soft tissues. Following injury, an inflammatory response occurs and the cells below the dermis begin to increase collagen production. Later, the epithelial tissue is regenerated¹. It is accepted that wound repair is an immune-mediated physiologic mechanism². Wound healing, or wound repair, is an intricate process in which the skin repairs itself after injury³. There are various natural agents, which assist in wound healing process. The plant's wound healing process is promoted through several of its constituents, including active principles like flavonoids, triterpenes and alkaloids⁴. Essential trace elements, especially zinc and vitamin C, also influence the process of wound repair. They act as co-factors or coenzymes in a number of metabolic functions involved in wound healing⁵. Several phytochemical and pharmacological investigators found that most of the tribal people are using *Thespesia macrophylla* mainly for wound healing activity, apart from in other conditions. It was also found that few works has been reported regarding its pharmacology and phytochemistry. So in the present study emphasis will be laid on the pharmacological screening of the plant with special reference to the above

mentioned activities. The present experimental investigation will be an attempt to give scientific justification to the acclaimed activities.

MATERIALS AND METHODS

Drugs and Chemicals

Standard nitrofurazone ointment was obtained from Cipla Pvt Ltd; Wool fat, Hard Paraffin, Cetosterayl alcohol, White Soft Paraffin and 90% Ethanol were purchased from SD Fine Chem Ltd, Mumbai; all other chemicals used for the study were of analytical grade.

Plant material

Root of the *Thespesia macrophylla* was collected from village Nangavalli, Salem district of Tamil Nadu, India. The plant material was authenticated from Dr P.Jayaraman, Plant Anatomy Research Centre, Chennai, TamilNadu India.

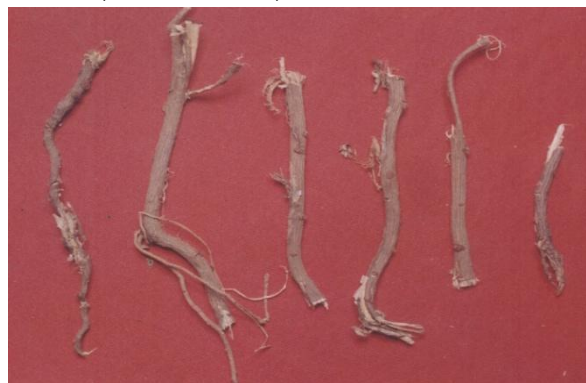

Fig 1. Roots of *Thespesia macrophylla*

A. Preparation of ethanolic extract

The shade dried coarse powder of roots of *Thespesia macrophylla* (250gm) was packed well in a soxhlet apparatus and was subjected to continuous hot

extraction with 90% ethanol for 18 hours. The extract was filtered while hot the resultant extract was distilled in vacuum under reduced pressure in order to remove the solvent completely. It was dried and kept in a desiccator for future experiments. The extract obtained was weighed and percentage yield was calculated in terms of air-dried powdered crude material⁶.

B. Preparation of aqueous extract

The shade dried coarse powder of the roots (250gm) was packed well in soxhlet apparatus and was subjected to continuous hot extraction with distilled water until the completion of extraction. The extract was filtered while hot and the resultant extract was distilled in vacuum under reduced pressure in order to remove the distilled water completely. It was finally dried and kept in a desiccators till experimentation. Obtained extract was weighed and percentage yield was calculated in terms of air-dried powdered crude material.

C.Preparation of ointment by fusion method:

(a) Preparation of simple ointment

Wool fat - 2 gm; Hard Paraffin-2 gm; Cetosterayl alcohol -2gm; White Soft Paraffin-34 gm. Each ingredient was mixed and heated gently with stirring then cooled. The base was then packed in a wide mouth container ⁷.

(b)Preparation of 5% w/w aqueous and ethanolic extracts ointment

5 gm aqueous and ethanolic root extracts of *Thespesia macrophylla* each

was added slowly to the base melted ingredients separately and stirred thoroughly until the mass cools down and a homogeneous product is formed⁷. The ointments were prepared then packed separately in a wide mouth container.

Animals

Wistar albino rats of either sex, weighing about 150–250 g each, were used for the study. They were fed with standard chow (Pranav Agro Industries Ltd., Sangli, Maharashtra) and water *ad libitum*. They were housed in polypropylene cages maintained under standard conditions (12h light - dark cycle; 25 ± 3 °C; 35–60% humidity). The experimental protocol was subjected to the scrutiny of the Institutional Animal Ethics Committee, (CPESEA) PCP/2012/066 and was cleared by same before beginning the experiment.

METHODS

Acute skin toxicity study⁸

Wistar albino female rats of 150-250 g weight and age of 90 days were used to determine the dermal toxicity of test extracts. The toxicological study was carried out to determine the therapeutic dose of ethanol extract as per the OECD guidelines. Testing of the ethanolic extracts was done by applying the aqueous and ethanolic extracts of the highest concentration on the shaved dorsal sides of the rats. It was observed that the dose was safe and lower dose was considered for further study.

Animal testing

Excision wound model

Hairs were removed from the dorsal thoracic central region of anaesthetised rats. The rats were depilated on the back. One excision wound was inflicted by cutting away a 300 mm² full thickness of skin from a predetermined area using toothed forceps, a surgical knife and pointed scissors⁹. The wound was left undressed to the open environment, the animals were randomly divided into the following four groups of 6 animals each: Group 1 (control) animals were topically applied with simple ointment prepared; Group 2 (experimental 1) animals were treated topically with the 5% ethanolic extract of *Thespesia macrophylla* ointment; Group 3 (experiment 2) animals were treated with 5%w/w aqueous extract of *Thespesia macrophylla* ointment and Group 4 (standard) animals were topically applied with nitrofurazone ointment. This was done every day and special care was taken to avoid the variation in the dose applied. The wound closure rate was assessed by tracing the wound on 2,4,8,12 & 16 etc days using transparency paper and areas recorded were measured using a graph paper and calculated the percent reduction in wound area by equation below.

$$\% \text{ Wound contraction} = (\text{Healed area} / \text{total area}) \times 100$$

Epithelialisation time was noted as a number of days after wounding required for the scar to fall off leaving no raw wound behind.

Linear Incision Wound Model

All the animals were anaesthetized and the hairs on the back of the rats were removed. A linear-paravertebral incision of 6 cm long was made with a sterile surgical blade through the full thickness of the skin 1 cm away from the midline of the vertebral column. After the incision was made, the parted skin was kept together and stitched with black silk at 1 cm apart; surgical threads (No.000) and a curved needle (no.11) were used for stitching¹⁰. The continuous threads on both wound edges were tightened for good closure of the wound. The wound was left undressed. The animals were divided into four major groups: those treated with the extracts, the reference drug and simple ointment (control group). The aqueous and ethanolic extract ointments, the reference drug (nitrofurazone) and the simple ointment were applied topically twice in a day throughout 9 days. All the sutures were removed on the 9th post-wound day. On Day 10 all the animals were killed under anesthesia. A linear paravertebral incised skin of each animal was measured for tensile strength using a tensiometer (Zwick/Roell Z0.5, Germany).

Statistical analysis

The values were calculated as mean \pm S.E.M. The significance of the difference of the mean value with respect to control group was analyzed by one way ANOVA followed by Dunnet's t-test using Statistica 8.0. P<0.05 or above was considered to be significant.

RESULTS AND DISCUSSION

The results of excision wound model are shown in tab 1.

In excision wound model the 5% ethanolic extract ointment of *Thespesia macrophylla*, manifested 99% wound contraction on the 16th day, which is moderately significant with standard Nitrofurazone ointment used. The 5% aqueous extract ointment was exerted 95% wound contraction on the 16th day which lies in appreciable limit.

The data obtained from both 5% aqueous extract and 5% ethanolic extract sample ointment of *Thespesia macrophylla*, the same (Fig.2).

In case of, the linear incision wound model, the tensile strength of the incision wound found that the topical application of ethanolic extract of the *Thespesia Macrophylla* showed significantly higher than the aqueous extracts, whereas control group showed much lesser tensile strength needed to break the wound than the extracts treated groups (Tab. 3 and Fig 4).

The result describes some unique features of the root extract from the plant *T. macrophylla* with respect to its potential wound healing capacity in rats. Plant products are potential wound healing agents, and largely preferred because of their widespread availability, non-toxicity, absence of unwanted side effects, and effectiveness as crude preparations.

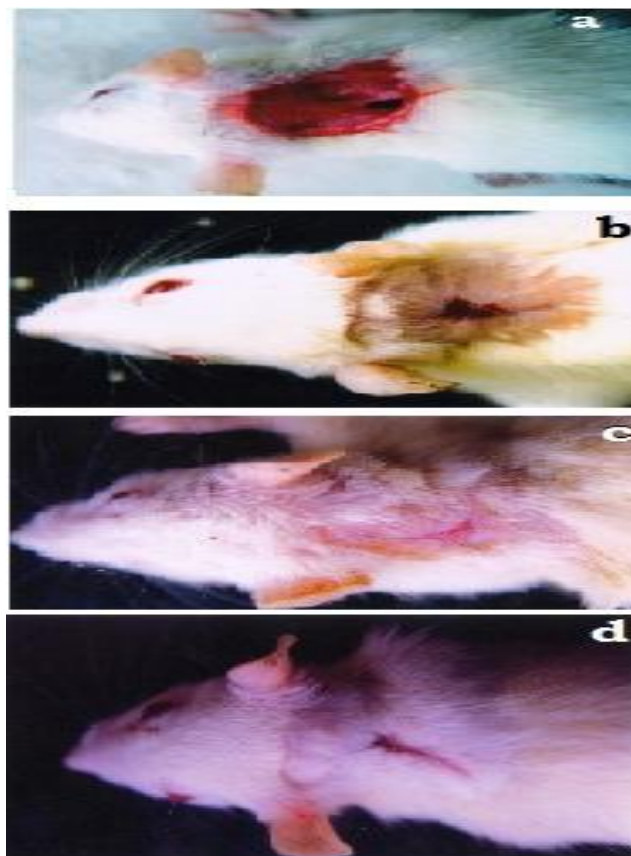


Fig 2. depicts (a) is the wound of control at 0 day; (b), (c) and (d) are the wound of aqueous extract, ethanolic extract and standard treatments at 16th day respectively.

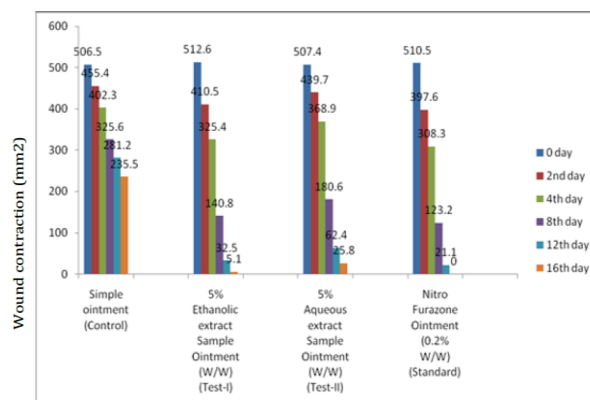


Fig 3. Graphical Representation of *Thespesia Macrophylla* Root Extracts on Excision Wound Model

Tab 1. Effect of *Thespesia Macrophylla* Roots Extract on Excision Wound Model

Drug	Wound contraction (mm ²) on day ± S.E and percentage of wound contraction					
	0 day	2 day	4day	8 day	12 day	16 day
Simple ointment (Control)	506.5 ±4.61 (0.0)	455.4 ±5.71 (10.0)	402.3 ±7.1 (20.5)	325.6 ±3.3 (35.7)	281.2 ±3.3 (44.5)	235.5 ±4.1 (53.5)
5% w/w Ethanolic extract Ointment (test1)	512.6 ±3.5 (0.0)	410.5 ±5.6 (19.9)	325.4 ±6.1 (36.51)	140.8 ±4.3 (72.53)	32.5** ±1.5 (93.65)	5.1** ±0.3 (99.0)
5% w/w aqueous extract Ointment (test2)	507.4 ±4.7 (0.0)	439.7 ±7.5 (13.3)	368.9 ±5.6 (27.29)	180.6 ±4.2 (64.4)	62.4* ±3.8 (87.7)	25.8** ±1.1 (94.9)
0.2% w/w Nitrofurazone Ointment (Standard)	510.5 ±5.1 (0.0)	397.6 ±5.9 (22.1)	308.3 ±5.0 (39.6)	123.2 ±3.4 (75.8)	21.1** ±1.4 (95.8)	0.00*** -- (100)

Values are mean ± S.E.M of animals in each group
P < 0.01 Vs Control by student 't' test.

Tab 2. Time required for wound healing by *Thespesia macrophylla* root extract in rats.

Animal groups	no of animals	type of treatment	healing time (days)(Mean±SEM)
Group1	6	simple ointment	20.0± 2.0 ^a
Group2	6	5%w/w aqueous extract	18.0 ± 0.2 ^b
Group3	6	5%w/w ethanolic extract	16.0 ± 2.3 ^b
Group4	6	nitrofurazone ointment	15.0 ± 2.3 ^b

All values were expressed as mean and + standard error mean. Mean with different superscripts are significantly different (P<0.05).

Earlier it was reported that *Centellaasiatia* and *Terminaliachebula* are effective in wound healing in rats. Various activities were conducted in this study to evaluate the potential of *T. macrophylla* wound healing agent. One such activity is the phytochemical screening test. The phytochemical result reveals the presence of tannins, alkaloids, reducing sugars and steroids in the ethanolic root extract.

The constituents of the root extract, such as terpenoids and alkaloids⁴, may play a major role in the wound healing process observed in this study. On observations made visually, the wound contraction, a

due to enhanced migration of fibroblasts and epithelial cells to the wound site was observed during the wound healing process in the treated group.

A close examination of wound revealed that tissue regeneration was much quicker in the treated group compared to that in control wounds. Early dermal and epidermal regeneration in the treated group confirmed that the ointment containing the *T. macrophylla* extract had a positive effect toward cellular proliferation, granulation tissue formation, and epithelialization. The treated rats showed marked epithelialization, a moderate amount of

Tab 3. Effects of *Thespesia Macrophylla* Roots on Incision Wounds

Drugs	grams± S.E.M
Control (Simple ointment)	192.8 ± 8.4
5%w/w alcoholic extract ointment	450.4 ± 4.2 **
5%w/w aqueous extract ointment	352.5 ± 7.2 *
Standard (Nitrofurazone) ointment	575.45 ± 8.9 ***

N = 6 Mean ± S.E.M, P > 0.01 Vs Control by student 't' test

part of the proliferative phase of wound healing, occurs through the centripetal movement of the tissues surrounding the wound, which is mediated by myofibroblasts (Fig 2 &5). The increased wound contraction in the treated group may be due to the enhanced activity of fibroblasts *T. macrophylla* root extract. A remarkably increase in collagen content

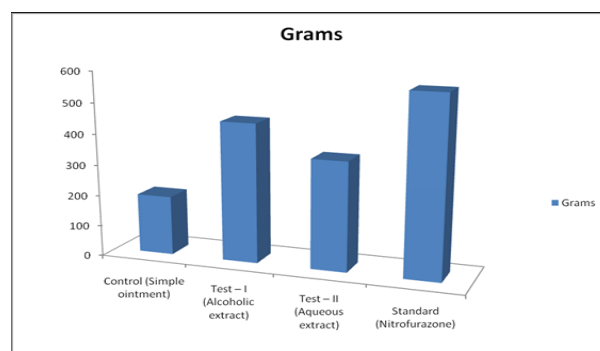


Fig 4. Graphical Representation of *Thespesia Macrophylla* Root Extract on Incision Wound Model

extracellular matrix synthesis and new blood vessel formation.

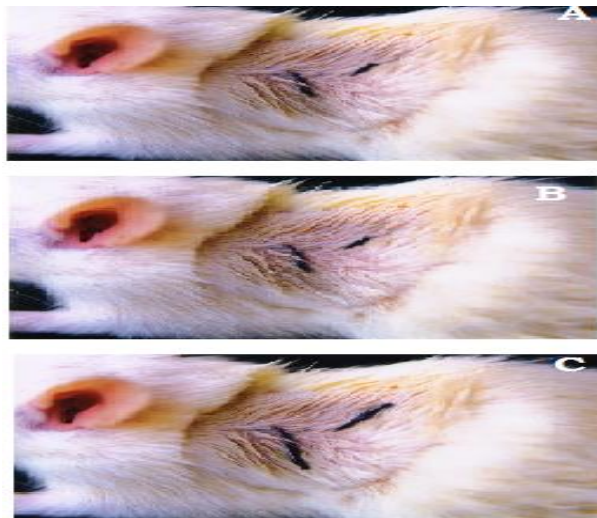


Fig 5. Photographs A, B & C depicts curing of Incision wound treated with Nitrofurazone ointment, aqueous extract and ethanolic extracts treated

CONCLUSION

The results obtained in the present studies clearly indicate that the Ethanolic root extract of *Thespesia macrophylla* was having significant wound healing activity in rats. The wound healing effect of ethanolic root extracts of *Thespesia macrophylla* may be due to the presence of more than one active principle. Further pharmacological and bio-chemical investigation will clearly elucidate the mechanism of action and will be help full in projecting this plant as a therapeutic target in wound healing and other diseases.

Abbreviation used: OECD= Organization of Economic Co-Operation and Development.

REFERENCES

1. Souba W W, Wilmore D. Diet and nutrition in case of the patient with surgery, Truma and sepsis. In, Shils M, Olson J, Shike M, Ross AC, (ed). *Moderen Nutrition in Health and Disease*. Baltimore: Williams and Wilkins; 1999; 1589-1618.
2. Singer A J, Clark R A. Cutaneous wound healing. *N. Eng. J. Med.* 1999; 341: 73-746.
3. Nguyen D T, Orgill D P, Murphy G F. *The patho-physiologic basis for wound healing and cutaneous regeneration. Biomaterials For Treating Skin Loss*. Cambridge, Boca Raton: CRC Press (US) & Woodhead Publishing (UK); 2009; 25-57.
4. Sharma S P, Aithal K S, Srinivasan K K, Udupa A L, Kumar V. Kulkarni D R. Anti-inflammatory and wound healing activities of the crude alcoholic extracts and flavonoids of *Vitex leucoxylon*. *Fitoterapia* 1990;61: 263-265.
5. Bhar R, Maiti S K, Goswami T K, Patra R C, Garg A K, and Chhabra A K. Effect of dietary vitamin C and zinc supplementation on wound healing, immune response and growth performance in swine. *Indian Journal of Animal Sciences* 2003; 73 (6): 674-677.
6. Mukhargee PK. *Quality control of herbal drugs*. 1st ed. Calcutta : , Business horizons pharmaceutical publishers; 2002.
7. Chatterjee T K and Chakravorthy A. Wound healing properties of the new antibiotics (M181) in mice. *Indian drugs* 1993; 30 45.

8. Shenoy C, Patil M B, Kumar R, Patil S. Preliminary phytochemical investigation and wound healing activity of *Allium cepa* linn (liliaceae). Int J Pharm Pharmaceut Sci 2009; 2(2):167-175.
9. Ilango K, Chitra V. Wound Healing and Antioxidant activities of Fruit pulp of *Limonia acidissima* Linn (Rutaceae) in Experimental animals. Tropical Journal of Pharmaceutical Research 2010; 9 (3):223-230.
10. Srinivas K R, Gnananath K, Sanjeeva A K, Vinay D K, Krishna B. Evaluation of in vivo wound healing potential of *Cassia roxburghii* leaves extracts. Der Pharmacia Sinica 2011; 2 (6): 32-38.

Cited this article as: Swetha P, RajKumar M, Krishnamoorthy B, Muthukumaran M, Sujana V. Wound-healing potential of aqueous and ethanolic extracts of *thespesia macrophylla* blume. roots - A preliminary study. Int J Adv Pharm Gen Res 2013; 1(1): 30-38.